


KMCT

COLLEGE OF ALLIED HEALTH SCIENCES

Affiliated to Kerala University of Health Sciences and approved by Govt. of Kerala


2.5.4 Retest and answer sheets




Principal
KMCT College of Allied Health Sciences
P.O. Manassery, Mukkam
Kozhikode, Pin - 673602


Muthalam, Mukkam, Kozhikode - 673602

☎ 0495-2296522, 2986522, 9526013000

✉ healthscience@kmct.edu.in  www.kmcthealthsciences.org



INNOVATION AND
ENTREPRENEURSHIP
DEVELOPMENT CENTRE



KMCT

COLLEGE OF ALLIED HEALTH SCIENCES

Affiliated to Kerala University of Health Sciences and approved by Govt. of Kerala

General anatomy

Angela Vignese
Ballarín
Pisc. optometry

10/20

- Thyroid gland
 - Pituitary gland.
 - Superior gland.
- Thyroid gland

- Largest endocrine gland in the body.
- ~~less~~ depends on external environment for material to synthesise the hormones.
- It is the only endocrine gland that is located in the superficially of the body.
- It has high rich blood supply secretes T₃ and T₄ hormones

Measurements

- length - 10cm
- breadth - 5cm
- Thickness - 2cm
- weight - 25g

Location

located in the anterior part both side of the trachea opposite to C₁, C₂, C₃ vertebrae.

Parts


- 3 lateral lobules. connective withness.
- 2 borders
- It shaped
- weight - 150gm



[Signature]

Principal
KMCT College of Allied Health Sciences
P.O. Manassery, Mukkam
Kozhikode, Pin - 673602






2nd Internal Examination General anatomy

Stomach

- most widest and distensible part of GI tract
- acts as Reservoir of food
- it mixes the food with gastric juice
- makes chyme
- HCl secreted by gastric gland to destroy the bacteria in the food.
- Location - Epigastric region
Left Hypochondriac region
Umbilicus



Shape - J shaped in living body
Sickle like shaped in Cadaveric position
Capacity - 150 ml [at birth]
90-100 ml [at adult]

External features


- Two ends - Cardiac, Pyloric
- Two curvatures - Lesser, Greater
- Two Surfaces - Anteroposterior, Anterosuperior


Cardiac end

- joins from the lower end of Oesophagus
- Present Cardiac Pylorus
- less mobile and lies 10cm deep into anterior abdominal wall.
- lies 2.5cm left to the midline.


Pyloric end

- joins proximal part of duodenum.
- has more mobile.




Principal
KMCT College of Allied Health Sciences
P.O. Manassery, Mulkam
Kozhikode, Pin - 673602





KMCT

COLLEGE OF ALLIED HEALTH SCIENCES

Affiliated to Kerala University of Health Sciences and approved by Govt. of Kerala

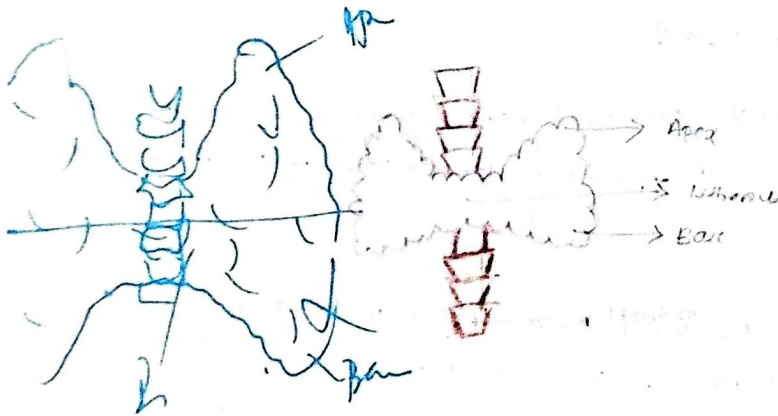
Aneera daniel
ROLL NO: 4.

General anatomy

- Endocrine gland:
 - Thyroid gland.
 - Pituitary gland.
 - Suprarenal gland.



Thyroid gland




- It is the largest endocrine gland.
- It lies superficial to the body.

External feature.

- It has 2 lateral lobes. in pyramidal shape.
- They are connected by isthmus.
- It has 2 and 3 surface:
 - Anterolateral surface
 - posterolateral "
 - medial "

2 borders: Anterior superior




(Signature)
Principal
KMCT College of Allied Health Sciences
P.O. Manassery, Mukkam
Kozhikode, Pin - 673602






General anatomy

- esophagus
- Salivary gland
- Tongue
- Pharynx
- Esophagus
- Duodenum
- Stomach
- Large intestine
- Small intestine
- Caecum and appendix
- Rectum



Stomach



- Stomach is the coiled and distensible part
- It secrete ~~ate~~ produce gastric juice and mixes it with food and mastic chyme.
- It act as reservoir of food.
- It secrete HCl that kill the bacteria

• Location: left hypochondriac region, epigastric region, umbilical.

• shape: J shape



[Signature]
Principal
KMCT College of Allied Health Sciences
P.O. Manassery, Mukkam
Kozhikode, Pin - 673602





KMCT

COLLEGE OF ALLIED HEALTH SCIENCES

Affiliated to Kerala University of Health Sciences and approved by Govt. of Kerala



General Anatomy


Deviha Sathyan

Roll no: 8

1st year optometry

kmct, CAHS

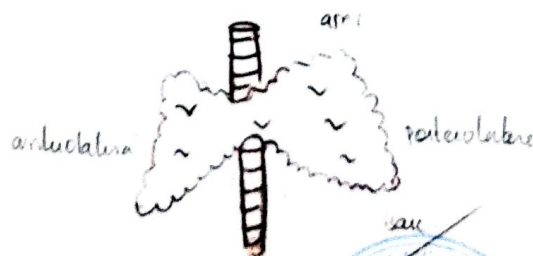1. endocrine glands
- pituitary gland
 - supra renal gland
 - Thymus gland
 - Thyroid gland
 -
 -
 -




Thyroid gland

- it is the largest gland in endocrine glands.
- it is not the ^{supra} superficially only gland located superficially in the body.
- it lies ^{opposite} C₅, C₆, C₇ & T₁ vertebrae
- it located lateral & side of trachea

Parts




- It has apex & base
- 3 surface: antrolateral surface, posterolateral surface



[Signature]
Principal

KMCT College of Allied Health Sciences
P.O. Manassery, Mukkam
Kozhikode, Pin - 673602





KMCT


COLLEGE OF ALLIED HEALTH SCIENCES

Affiliated to Kerala University of Health Sciences and approved by Govt. of Kerala

Devika Sajithumma

Roll no: 8

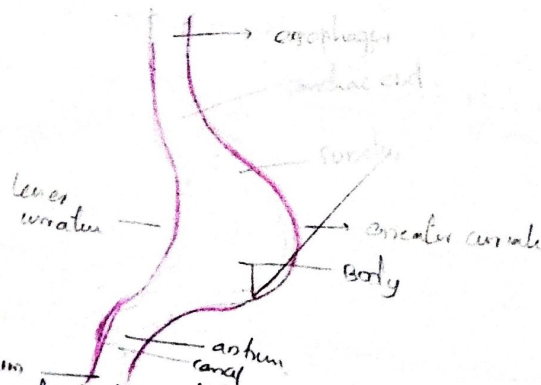
General Anatomy



Gastro-Intestinal tract

- Mouth
- Tongue
- pharynx
- oesophagus
- Stomach
- Small intestine
- Large intestine
- liver
- pancreas
- duodenum
- caecum & appendix
- anal canal & rectum


Stomach



- stomach is the widest and distensible part
- it mix the food with gastric juice & make it chyme
- it act as a reservoir of food
- HCL produced by this, it destroy the bacteria in food
- stomach produce gastric juice

Devika
 College of Allied Health Sciences
 P.O. Manassery, Mukkam
 Kozhikode, Pin - 673602





KMCT

COLLEGE OF ALLIED HEALTH SCIENCES

Affiliated to Kerala University of Health Sciences and approved by Govt. of Kerala


General Anatomy

Hyla. P. 2
Roll no: 14
1st year bsc
Anatomy

6. Eyeball

Eyeball " act as the camera.
eye has many parts, retina, cornea, lens, etc.
help to visualize

" Situated in the hole of the skull



7. Lymph node

Lymph node is the small pear shaped structure.
It is the wedge shaped

colour is pulplish red.
thickness is 1cm

9. Structure of the skin

Skin is the largest sense organ of the body
it covers all the external part
8% of total body mass

thickness is about 1.5 to 4mm

They are 4 parts for the skin


- Stratum basale
- Stratum spinosum
- Stratum granulosum
- Stratum lucidum
- Stratum corneum

4. Cerebellum is the largest endocrine gland part of the brain

it help to
Stratum basale


it is the outermost part of the skin

• Skin has two parts
thick skin and thin skin



Principal
KMCT College of Allied Health Sciences
P.O. Manassery, Mukkam
Kozhikode, Pin - 673602






General Anatomy

Hyfa A.R
Roll no. 14
BSc Optometry

parts of gastro-intestinal tract

- mouth
- trachea
- oesophagus
- stomach
- large intestine
- small intestine.

Write in order!



Stomach

- Stomach is the most widest and distensible part of GIT
- it act as receiver of food.
- gastric gland. produce gastric juice and make it chyme.
- HCl produce in stomach and destroy the bacteria of the food.

location

left hypochondria, umbilical, epigastric region.


length

at birth = 30cm
in adult = 1500 to 2000.

- few surface
- two ends
- two curvatures

Cardiac end

- it joint the upper part of stomach.
- it prevent the reflux of food.
- it is mobile and lie 2.5 cm to left median plane



Principal
KMCT College of Allied Health Sciences
P.O. Manassery, Mukkam
Kozhikode, Pin - 673602

